

12

AUTOPSY REPORT

No.

2020-09706

WILLIAMS, FRED

I performed an autopsy on the body of →

at the DEPARTMENT OF MEDICAL EXAMINER-CORONER

Los Angeles, California on OCTOBER 21, 2020 1000 HOURS
(Date) (Time)

From the anatomic findings and pertinent history I ascribe the death to:

(A) GUNSHOT WOUND OF BACK

DUE TO OR AS A CONSEQUENCE OF

(B)

DUE TO OR AS A CONSEQUENCE OF

(C)

DUE TO OR AS A CONSEQUENCE OF

(D)

OTHER CONDITIONS CONTRIBUTING BUT NOT RELATED TO THE IMMEDIATE CAUSE OF DEATH

MANNER OF DEATH

HOMICIDE

HOW INJURY OCCURRED

SHOT BY LAW ENFORCEMENT OFFICER

Anatomic Summary:

The decedent was a 25-year-old Black male who was shot by law enforcement officer. He was pronounced at the scene

I. Gunshot wound of left back:

- A. The entrance wound is round shaped and measures 3/8 of an inch. The entrance wound is situated at the left back 12 inches from top of the head and 7 inches left from midline. Soot or stippling is not present. The surrounding skin has 1/16 of an inch abrasion.
- B. There is no exit wound.
- C. The projectile was recovered from the liver 20 inches from the top of the head, 5 inches right from midline, and submitted for evidence.
- D. The direction of the wound is left to right, downward, and slightly back to front.
- E. The wound path enters through the skin, left rib #5 lateral with fracture, left lung, aorta, probable vertebra graze, right lung, diaphragm, terminating in the right lobe of the liver.

12**AUTOPSY REPORT**

No.

2020-09706

WILLIAMS, FRED

Page 2

F. Associated injuries: Left hemothorax 500 cc, right hemothorax 900 cc.

EXTERNAL EXAMINATION:

The body is identified by toe tags and is that of an unembalmed, refrigerated adult Black male who appears about the reported age of 25 years. The body weighs 250 pounds, measures 72 inches, and is well built. The skin is free of abrasions, bruises, and lacerations. There are lesions on the skin consistent with postmortem insect activity. Tattoos are present. Please see autopsy photographs.

The head is normocephalic and covered by black hair. Short mustache and short beard are present. Examination of the eyes reveals irides that appear to be brown in color and sclerae that are white. There are no petechial hemorrhages. Upper and lower teeth are present. The neck is unremarkable. There is no chest deformity. The abdomen is not unusual. The external genitalia are without trauma or lesions.

EVIDENCE OF THERAPEUTIC INTERVENTION:

There is no evidence of any recent hospitalizations.

CLOTHING:

The body was not clothed, and the clothing was not available at the time of the autopsy.

INITIAL INCISION:

The body cavities are entered through the standard coronal and the standard Y-shaped incisions.

12**AUTOPSY REPORT**

No.

2020-09706

WILLIAMS, FRED

Page 3

NECK:

The neck organs are removed en bloc with the tongue. There are no lesions to the lips or oral mucosa. Larynx and hyoid are intact. The tongue when sectioned shows no trauma.

CHEST/ABDOMINAL CAVITY:

The right pleural cavity contains 900 cc of blood. The left pleural cavity contains 500 cc of blood. The lungs are partly collapsed. The subcutaneous fat of the abdominal wall measures from 1.5 to 2.0 inches. The organs of the abdominal cavity have a normal arrangement, and none are absent. There is minimal blood collection surrounding the liver.

CARDIOVASCULAR SYSTEM:

The aorta is fairly elastic. There is 3/4 of an inch laceration of the thoracic aorta caused by gunshot wound. The pericardial sac contains serous fluid. The weight of the heart is 500 grams. The left ventricle is slightly enlarged. The myocardium, coronary arteries, and valves are unremarkable. There is no blood within the heart and large blood vessels due to bleeding.

RESPIRATORY SYSTEM:

Trachea and bronchi are unremarkable. The weight of the right lung is 260 grams. The weight of the left lung is 240 grams. There is a gunshot wound through the left lung lower lobe surrounded by contusions/hemorrhage. There is a gunshot wound through the right lung lower lobe surrounded by contusion/hemorrhage. The parenchyma of the lungs is otherwise unremarkable.

12**AUTOPSY REPORT**

No.

2020-09706

WILLIAMS, FRED

Page 4

GASTROINTESTINAL SYSTEM:

The esophagus is intact. The stomach contains approximately 200 cc of food remains. The small intestine and colon are examined by inspection, palpation, and multiple incisions and show no pathology. The appendix is present. The pancreas has no trauma.

HEPATOBIILIARY SYSTEM:

The liver weighs 1180 grams. There is a gunshot wound through the right lobe of the liver. The projectile was recovered from the right side of the liver and submitted for evidence. The parenchyma of the liver has early decomposition changes. The gallbladder contains a few cc of bile and no calculi.

URINARY SYSTEM:

The left kidney weighs 130 grams. The right kidney weighs 130 grams. The parenchyma of the kidneys is grossly unremarkable. The urinary bladder contains a few cc of cloudy urine.

GENITAL SYSTEM (MALE):

The prostate is unremarkable. Both testes are in the scrotum and without trauma.

HEMOLYMPHATIC SYSTEM:

The spleen weighs 120 grams. Lymph nodes throughout the body are small and inconspicuous.

ENDOCRINE SYSTEM:

The thyroid gland, adrenal glands, and pituitary glands are unremarkable. The thymus is unremarkable for its age.

12**AUTOPSY REPORT**

No.

2020-09706

WILLIAMS, FRED

Page 5**HEAD AND CENTRAL NERVOUS SYSTEM:**

There is no hemorrhage in the scalp. There are no fractures of the calvarium or base of the skull. There is no epidural, subdural, or subarachnoid hemorrhage. The brain weighs 1550 grams. The leptomeninges are thin and transparent. A normal convolutionary pattern is observed. Coronal sectioning demonstrates a uniformity of cortical gray thickness. The cerebral hemispheres are symmetrical. There is no hemorrhage of the white matter. The basal ganglia are intact. Cerebral contusions are not identified. The ventricular system is unremarkable. Pons, medulla, and cerebellum are unremarkable.

SPINAL CORD:

The spinal cord was not dissected.

HISTOLOGIC SECTIONS:

Representative sections from various organs are preserved in one storage jar in 10% formalin.

TOXICOLOGY:

Chest blood, femoral blood, EDTA blood, urine, stomach contents, and vitreous have been submitted to the lab. A comprehensive screen was requested.

PHOTOGRAPHY:

At scene photos are available. Photographs have been taken prior to and during the course of the autopsy.

12**AUTOPSY REPORT**

No.

2020-09706

WILLIAMS, FRED

Page 6

RADIOLOGY:

The body is fluoroscoped and two x-rays are taken. The x-rays show projectile in right side of the body.

WITNESSES:

Lieutenant Hall, Sergeant O'Brien, Inspector Kase, Detective Dimmitt, Investigator Field, and Investigator Garcia witnessed the autopsy.

DIAGRAMS USED:

Diagram Forms #16, 20, and 52 were used during the performance of the autopsy.

OPINION:

The decedent died due to gunshot wound of back.



VADIMS POUKENS, M.D.
DEPUTY MEDICAL EXAMINER

10/28/20
DATE

VP:bbtt/b
D:10/21/20
T:10/22/20

52

GUNSHOT WOUND

FOLLOW FORM EXACTLY AS PRINTED
CIRCLE OR CHECK ONE OR THOSE THAT APPLY
REMEMBER THE FORM IS PRINTED ON BOTH SIDES

NO.

2020-09706

WILLIAMS, FRED

page 1 of 2

L. back

The **entrance** wound is *O* shaped and measures *3/8* inches

The entrance wound is situated at the *L. back*
12" TOP, 7" ROM is centered _____ inches from the vertex / external auditory meatus and _____ inches to the left / right of midline.

Shooting is present and measures _____ inches. A muzzle imprint is present is not absent

Stippling and / or tattooing can be described as _____ and the spread measures _____ inches. The surrounding skin *1/16" split*

There is no exit wound **OR**

The **exit** wound is _____ shaped and measures _____ inches

The wound exit is situated at the _____ is centered _____ inches from the vertex / external auditory meatus and _____ inches to the left / right of midline.

It is oriented diagonal parallel perpendicular

to the long axis of the body.

No **projectile** was recovered at autopsy.
 The projectile was recovered from the *Liver* *20" TOP, 5" ROM*
and submitted for evidence or released to the evidence custodian. It is described as: _____

GUNSHOT WOUND

The direction of the wound is

<input checked="" type="checkbox"/>	back to front
<input type="checkbox"/>	front to back
<input checked="" type="checkbox"/>	left to right
<input type="checkbox"/>	right to left
<input checked="" type="checkbox"/>	downwards
<input type="checkbox"/>	upwards

slightly

The wound path penetrates through the skin / mucosa of the

<input type="checkbox"/>	completely disrupts
<input type="checkbox"/>	penetrates
<input type="checkbox"/>	perforates

4.5 inch, 5 inch deep,
the *L. lung, aorta, probably vertebral*
spine, R lung, diaphragm
and penetrates into the _____ terminating at the *liver*

X-rays are taken of the following areas: _____

and show _____

Diagrams used: _____

Photographs obtained:

<input type="checkbox"/>	at scene
<input type="checkbox"/>	during examination

OPINION

This wound is

<input checked="" type="checkbox"/>	immediately life threatening
<input type="checkbox"/>	not immediately life threatening
due to	<input type="checkbox"/> hemorrhage of _____
	<input checked="" type="checkbox"/> the perforated <i>aorta</i>

Ass. inj. : - L. hemothorax 500 cc
R - " - 900 cc.

VADIMS POUKENS, M.D.

Vadims Poukens

10/21/20

20

Black ♂

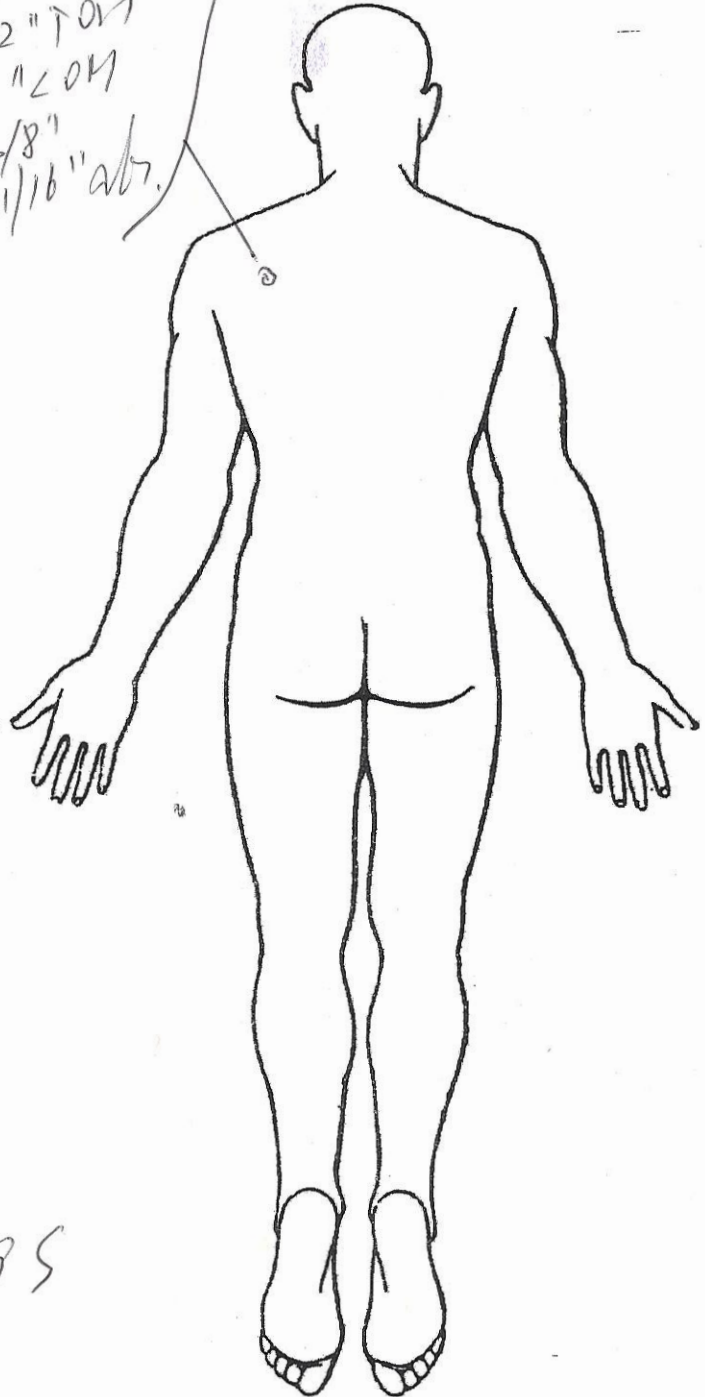
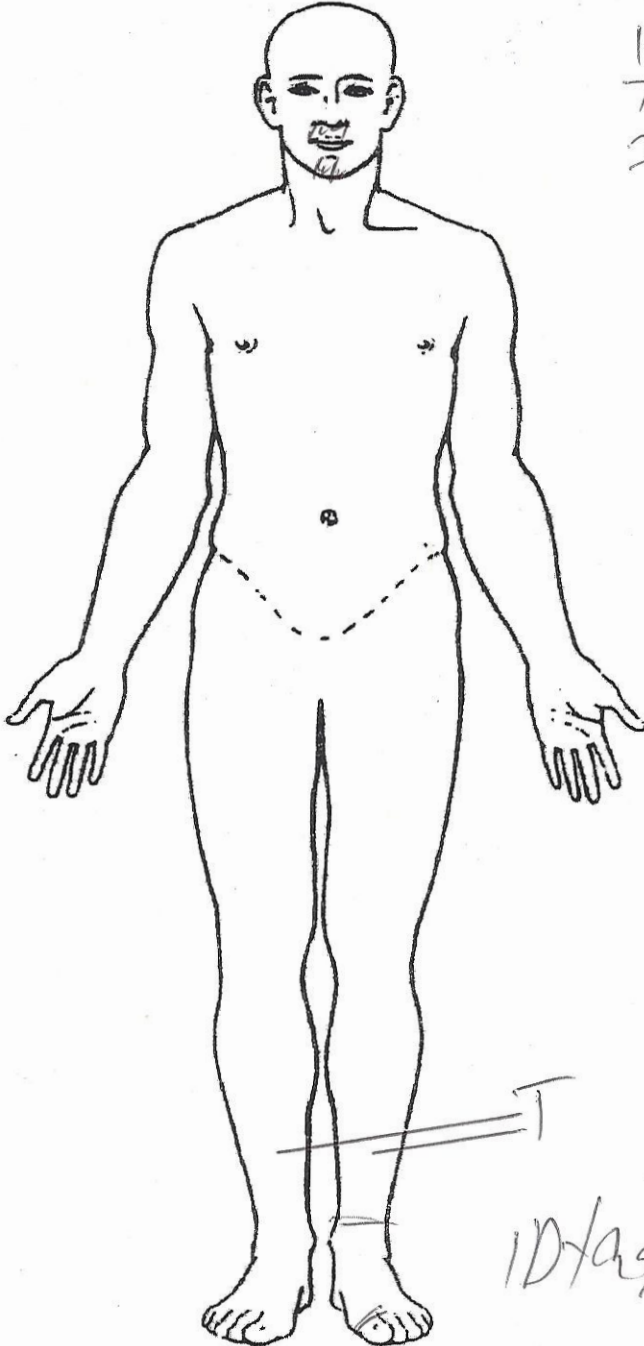
2020-09706

WILLIAMS, FRED

HOMI

475

9 SW wrist
12" T arm
7" L arm
3/8" neck
1/16" abd.



ID tags

VADIMS POUKENS, M.D.

Date

10/21/20

[Signature]

M.D.

Deputy Medical Examiner

Right Thumbprint

16

21st St Lat 11/21
22 V White, 90%
12 V White, 10%
B-17 1-2, V, B-F ±

2020-09706

WILLIAMS, FRED

HOMI

475

EXTERNAL EXAM

- Sex
- Race
- Age
- Height
- Weight
- Hair
- Eyes
- Sclera
- Teeth
- Mouth
- Tongue
- Nose
- Chest
- Breasts
- Abdomen
- Scar
- Genitals
- Edema
- Skin
- Decubitus

HEART Wt.

- Pericardium
- Hypertrophy
- Dilation
- Muscle
- Valves
- Coronaries

AORTA

VESSELS

LUNGS Wt.

- R
- L
- Adhesions
- Fluid
- Atelectasis
- Oedema
- Congestion
- Consolidation
- Bronchi
- Nodes

PHARYNX

TRACHEA

THYROID

THYMUS

LARYNX

HYOID

ABDOMINAL WALL FAT

PERITONEUM

- Fluid
- Adhesions

LIVER Wt.

- Capsule
- Lobules
- Fibros
- G B
- Calculus
- Bile ducts

SPLEEN Wt.

- Color
- Consistency
- Capsule
- Malpiment

PANCREAS

ADRENALS

KIDNEYS Wt.

- R
- L
- Capsule
- Cortex
- Vessels
- Pelvis
- Ureters

BLADDER

GENITALIA

- Prostate
- Testes
- Uterus
- Tubes
- Ovaries

OESOPHAGUS

STOMACH

- Contents

DUOD. & SM. INT.

APPENDIX

LARGE INT.

ABDOM. NODES

SKELETON

- Spine
- Marrow
- Rib Cage
- Long bones
- Pelvis

SCALP

CALVARIUM

BRAIN Wt.

- Dura
- Fluid
- Ventricles
- Vessels
- Middle ears
- Other

PITUITARY

SPINAL CORD

TOXICOLOGY SPECIMENS

SECTIONS FOR HISTOPATHOLOGY

MICROBIOLOGY

DIAGRAMS

X-RAYS

OTHER PROCEDURES

GROSS IMPRESSIONS

500
- 95w
200-95w
240-95w
2500
1290v

1180
95w bullet

120

130
130

a few

2000 food

f

1.5-2.0

VADIMS POUKENS, M.D.

Date 11/21/20

Time 1000

Deputy Medical Examiner

V. Poukens

15

AUTOPSY CLASS: A B C Examination Only D

FAMILY OBJECTION TO AUTOPSY

Date: 10/20/20 Time: 1000 Dr. Poukens

FINAL ON: 10/21/20 By: VADIMS POUKENS (Print)

APPROXIMATE INTERVAL BETWEEN ONSET AND DEATH

2020-09706 WILLIAMS, FRED HONI 475

DEATH WAS CAUSED BY: (Enter only one cause per line for A, B, C, and D)

IMMEDIATE CAUSE:

(A) Gunshot wound of back rapid

DUE TO, OR AS A CONSEQUENCE OF:

(B)

DUE TO, OR AS A CONSEQUENCE OF:

(C)

DUE TO, OR AS A CONSEQUENCE OF:

(D)

OTHER CONDITIONS CONTRIBUTING BUT NOT RELATED TO THE IMMEDIATE CAUSE OF DEATH:

Age 25 Gender: Male / Female

PRIOR EXAMINATION REVIEW BY DME

- BODY TAG CLOTHING
 X-RAY (No. 2) FLUORO
 SPECIAL PROCESSING TAG MED. RECORDS
 AT SCENE PHOTOS (No.)

CASE CIRCUMSTANCES

- EMBALMED
 DECOMPOSED
 >24 HRS IN HOSPITAL
 OTHER: (Reason)

TYPING SPECIMEN

TYPING SPECIMEN TAKEN BY: Source: W chest

TOXICOLOGY SPECIMEN

- COLLECTED BY:
 HEART BLOOD STOMACH CONTENTS
 FEMORAL BLOOD VITREOUS
 BLOOD SPLEEN
 BILE KIDNEY
 LIVER
 URINE

URINE GLUCOSE DIPSTICK RESULT: 4+ 3+ 2+ 1+ 0

TOX SPECIMEN RECONCILIATION BY:

HISTOLOGY

- Regular (No.) Oversize (No.)
Histopath Cut: Autopsy Lab

TOXICOLOGY REQUESTS

- FORM 3A: YES NO
 NO TOXICOLOGY REQUESTED
SCREEN C H T S D
 ALCOHOL ONLY
 CARBON MONOXIDE
 OTHER (Specify drug and tissue)

REQUESTED MATERIAL ON PENDING CASES

- POLICE REPORT MED HISTORY
 TOX FOR COD HISTOLOGY
 TOX FOR R/O INVESTIGATIONS
 MICROBIOLOGY EYE PATH. CONS.
 RADIOLOGY CONS.
 CONSULT ON:
 BRAIN SUBMITTED
 NEURO CONSULT DME TO CUT
 CRIMINALISTICS
 GSR SEXUAL ASSAULT OTHER

- NATURAL SUICIDE HOMICIDE
 ACCIDENT COULD NOT BE DETERMINED

If other than natural causes, HOW DID INJURY OCCUR?

Shot by leg officer

WAS OPERATION PERFORMED FOR ANY CONDITION STATED ABOVE: YES NO

TYPE OF SURGERY: DATE:

- ORGAN PROCUREMENT TECHNICIAN: M/H
PREGNANCY IN LAST YEAR YES NO UNK NOT APPLICABLE

- WITNESS TO AUTOPSY EVIDENCE RECOVERED AT AUTOPSY
Item Description:

1 projectile

VADIMS POUKENS, M.D.

[Signature]

RESIDENT

DME



Department of Medical Examiner-Coroner, County of Los Angeles

FORENSIC SCIENCE LABORATORIES

1104 North Mission Road, Los Angeles, CA 90033

Laboratory Analysis Summary Report



Poukens, Vadims M.D.

Deputy Medical Examiner
1104 North Mission Road
Los Angeles, CA 90033

PendingTox

Coroner Case Number: 2020-09706 **Decedent:** WILLIAMS, FRED

<u>SPECIMEN</u>	<u>SERVICE</u>	<u>DRUG</u>	<u>RESULT</u>	<u>ANALYST</u>
-----------------	----------------	-------------	---------------	----------------

Alcohol Quantitation/Confirmation

Blood, Chest

Alcohol-GC/FID-HS	Ethanol	Negative	C. Castellino
-------------------	---------	----------	---------------

Drug Screen

Blood, Chest

ELISA-Immunoassay	Benzodiazepines	ND	P. PfylCruz
ELISA-Immunoassay	Cocaine and Metabolites	ND	P. PfylCruz
ELISA-Immunoassay	Fentanyl	ND	P. PfylCruz
ELISA-Immunoassay	Marijuana: 11-nor-Delta-9-Carboxy-THC	PP	P. PfylCruz
ELISA-Immunoassay	Methamphetamine & MDMA	ND	P. PfylCruz
ELISA-Immunoassay	Opiates: Codeine & Morphine	ND	P. PfylCruz
ELISA-Immunoassay	Opiates: Hydrocodone & Hydromorphone	ND	P. PfylCruz
ELISA-Immunoassay	Phencyclidine	ND	P. PfylCruz

Drug Screen/Confirmation

Blood, Chest

Bases-GC/NPD &/or MS	Basic Drugs	ND	M. Liebl
Cannabinoids-LC/MS/MS	11-nor-Delta-9-Carboxy-THC, Free	Present	M. Liebl
Cannabinoids-LC/MS/MS	Delta 9-Tetrahydrocannabinol (THC), Free	26 ng/mL	M. Liebl

Blood, Femoral

Cannabinoids-LC/MS/MS	11-nor-Delta-9-Carboxy-THC, Free	Present	C. Castellino
Cannabinoids-LC/MS/MS	Delta 9-Tetrahydrocannabinol (THC), Free	24 ng/mL	C. Castellino

RP 11/13/20

<u>SPECIMEN</u>	<u>SERVICE</u>	<u>DRUG</u>	<u>RESULT</u>	<u>ANALYST</u>
-----------------	----------------	-------------	---------------	----------------


Legend:		ND	Not Detected	SNS	Specimen Not Suitable
g	Grams	ng/g	Nanograms per Gram	TNP	Test Not Performed
g%	Gram Percent	ng/mL	Nanograms per Milliliter	ug	Micrograms
Inc.	Inconclusive	PP	Presumptive Positive	ug/g	Micrograms per Gram
mg	Milligrams	QNS	Quantity Not Sufficient	ug/mL	Micrograms per Milliliter

The alcohol analysis was performed in accordance to California Code of Regulations "Title 17" compliance by a qualified analyst in the Forensic Toxicology Laboratory, Forensic Laboratories Division, County of Los Angeles Department of Medical Examiner - Coroner.

Enzyme-linked immunosorbant assay (ELISA) provides only a preliminary analytical result that is contingent upon a confirmatory test. A "presumptive positive" (PP) signifies a detection of a drug class and must be confirmed by additional testing for true identification and/or quantitation of specific drug(s) present in the specimen.

Per the Department's Evidence Retention Policy, the blood specimen(s) will be retained for one year (minimum) and all other specimens six months (minimum) from Postmortem Exam.

Final Review By:



Sarah Buxton de Quintana
Supervising Criminalist I

Date:

11/13/20

The above results relate only to the items sampled and tested and have been technically and administratively reviewed and are the opinions and conclusions of the analysts noted. The final review has been certified by the noted Toxicologist to ensure that all standard operating procedures were followed as set by the Forensic Toxicology Laboratory, Forensic Sciences Laboratory Division, County of Los Angeles Department of Medical Examiner-Coroner.

A Pentons

COUNTY OF LOS ANGELES

CASE REPORT

DEPARTMENT OF CORONER

1	APPARENT MODE HOMICIDE	CASE NO 2020-09706
	SPECIAL CIRCUMSTANCES Gunshot Wound, Media Interest, Victim of Crime, Officer Involved	CRYPT 475

LAST, FIRST MIDDLE WILLIAMS, FRED	AKA	#
---	-----	---

ADDRESS 2109 E 120TH ST	CITY LOS ANGELES	STATE CA	ZIP 90059
----------------------------	---------------------	-------------	--------------

SEX MALE	RACE APPEARS BLACK	DOB 2/11/1995	AGE 25	HGT 72 in.	WGT 250 lbs.	EYES BROWN	HAIR BLACK	TEETH ALL NATURAL TEETH	FACIAL HAIR BEARD	ID VIEW Yes	CONDITION FAIR
-------------	-----------------------	------------------	-----------	---------------	-----------------	---------------	---------------	----------------------------	-------------------	----------------	-------------------

MARK TYPE SCARS	MARK LOCATION FOREHEAD	MARK DESCRIPTION MULTIPLE LINEAR HEALED
TATTOO	CHEST	DESIGNS/SYMBOLS

NAME	ADDRESS	CITY	STATE	ZIP
------	---------	------	-------	-----

RELATIONSHIP	PHONE	NOTIFIED BY	DATE	TIME
--------------	-------	-------------	------	------

SSN	DL ID	STATE	PENDING BY
-----	-------	-------	------------

ID METHOD
FINGERPRINTS FROM DOJ

LA #	MILITARY #	POB CALIFORNIA
------	------------	-------------------

IDENTIFIED BY NAME (PRINT)	RELATIONSHIP	PHONE	DATE	TIME
----------------------------	--------------	-------	------	------

PLACE OF DEATH / PLACE FOUND PRIVATE RESIDENCE	ADDRESS OR LOCATION 2268 E 121ST STREET	CITY COMPTON	ZIP 90222
---	--	-----------------	--------------

PLACE OF INJURY PRIVATE RESIDENCE	AT WORK No	DATE 10/16/2020	TIME 17:30	LOCATION OR ADDRESS 2268 E 121ST STREET, COMPTON, CA	ZIP 90222
--------------------------------------	---------------	--------------------	---------------	---	--------------

DDO 10/16/2020	TIME 18:05	FOUND OR PRONOUNCED BY LACOFD ENG41 (JOHNSON)
-------------------	---------------	--

OTHER AGENCY INV. OFFICER LASD HOMICIDE - SGT. O'BRIEN/DIMMITT	PHONE (323) 890 5500	REPORT NO. 020156532136013	NOTIFIED BY	NO
---	-------------------------	-------------------------------	-------------	----

TRANSPORTED BY BRIAN BEY	TO LOS ANGELES FSC	DATE 10/17/2020	TIME 02:25
-----------------------------	-----------------------	--------------------	---------------

FINGERPRINTS? Yes	CLOTHING Yes	PARPT No	MORTUARY
MED. EV. No	INVEST. PHOTO # 36	SEAL TYPE NOT SEALED	HOSP RPT No
PHYS. EV. Yes	EVIDENCE LOG Yes	PROPERTY? Yes	HOSP CHART No
SUICIDE NOTE No	GSR NO	RCPT. NO. 322172	PF NO.

SYNOPSIS
ON 10/16/2020 AT APPROX. 1730 HOURS, DEPUTIES ON PATROL NOTED THE DECEDENT TO HAVE A WEAPON IN HIS HAND. DEPUTIES PURSUED THE DECEDENT ON FOOT. THE DECEDENT RAN INTO A PRIVATE RESIDENCE AND GOT ON TOP OF A SHED. THE DECEDENT THEN POINTED HIS WEAPON AT THE DEPUTY. THE DEPUTY SHOT AT THE DECEDENT, CAUSING THE DECEDENT TO FALL OVER INTO THE YARD OF THE HOUSE LOCATED BEHIND. DEPUTIES THEN FOLLOWED TO THE YARD THAT THE DECEDENT WAS LOCATED AT, TURNED THE DECEDENT OVER FROM A PRONE POSITION TO A SUPINE POSITION, AND GAVE THE DECEDENT CHEST COMPRESSIONS WITH CPR. PARAMEDICS FROM LOS ANGELES COUNTY FIRE DEPARTMENT ENG. 41 ARRIVED ON SCENE. PARAMEDIC JOHNSON DETERMINED DEATH ON 10/16/2020 AT 1805 HOURS. DETECTIVE DIMMITT AND SERGEANT O'BRIEN ARE REQUESTING A TWO-HOUR NOTIFICATION PRIOR TO THE EXAMINATION. PLEASE SEE CASE NOTES.

LIANNA DARABEDYAN 646370	<i>Lianna Darabedian</i> INVESTIGATOR	DATE 10/18/2020	REVIEWED BY <i>[Signature]</i>	DATE 10/18/2020
		TIME 02:00		TIME 0248

FORM #3 NARRATIVE TO FOLLOW?



County of Los Angeles, Department of Coroner
Investigator's Narrative



Case Number: 2020-09706

Decedent: WILLIAMS, FRED

Information Sources:

LASD Homicide, Sergeant O'Brien #273480, Report # 020156532136013 (323) 890-5500

Investigation:

On 10/16/2020 at 1912 hours, Deputy Bolanos from LASD Homicide made a first call to the Los Angeles County Medical Examiner-Coroner's office to report an apparent homicidal death of a 35-year-old male that was involved in an officer-involved-shooting and was struck by gunshot fire.

On 10/17/2020 at 0210 hours, Acting Watch Commander Weber assigned this case to me. I arrived on scene at 0125 hours and cleared the scene at 0205 hours. Captain Tauscher was present at the scene as well. Forensic Attendant Bey transported the decedent from the scene to the Forensic Science Center.

Prior to my arrival, Deputies moved the decedent from a prone position to a supine position to provide CPR. The Deputy's weapon (a Smith and Wesson M&P 9mm handgun with an unknown serial number) was collected as evidence by the police Investigation staff on scene. Another weapon was found at the scene (a Taurus 9mm handgun with serial [REDACTED] that was also collected as evidence by the police Investigation staff at the scene. The police investigation is ongoing.

Location:

Injury and Death: Private Residence, 2268 East 121st Street, Compton CA 90222.

Informant/Witness Statements:

I spoke with Detective O'Brien at the scene and he told me the following preliminary information:

The incident occurred on 10/16/2020 at approximately 1730 hours. Deputies in the area were doing patrol when they noted a group of individuals located at Mona Park. They observed the decedent with a weapon in his hand. The decedent took off running southbound through the parking lot. Deputies pursued the decedent on foot. The decedent then continued to run westbound on 122nd Street and then ran northbound into the driveway of a residence located at 2255 East 122nd Street Compton, CA 90222. The Deputies continued the pursue on foot. The decedent then jumped on top of a shed and pointed his weapon at the Deputy. The Deputy then shot the decedent. The shooting caused the decedent to fall over into the yard of a house located just behind (2268 East 121st Street, Compton CA 90222). The Deputies followed up to the yard that the decedent was located at. The decedent was located lying prone on the ground. The Deputies rolled the decedent over to a supine position and provided CPR with chest compressions. Paramedics from Los Angeles Fire Department Eng. 41 arrived on scene. Paramedic Johnson determined death at 1805 hours. A total of 8 casings were found at the scene. The police investigation is ongoing.

Scene Description:

The scene is a private residence located at 2268 East 121st Street in Compton. The yard area is located in the southern portion of the residence property. The yard was dimly lit and contained dry hay-like grass on the ground. The decedent was seen lying supine on the ground in the southeastern portion of the yard and had ant activity on him. Located on the ground, a few feet northwest of the decedent is a bloody white t-shirt. Located a few feet southeast of the decedent is a doghouse. Located a few feet east of the decedent is a pole and then a bicycle lying on the ground by it.

Located a few feet south of the decedent had apparently been the decedent's weapon (a Taurus 9mm handgun with serial [REDACTED] which was collected by the police investigation staff and placed in an evidence box prior to my arrival.



County of Los Angeles, Department of Coroner
Investigator's Narrative



Case Number: 2020-09706

Decedent: WILLIAMS, FRED

Due to safety concerns, the second portion of the crime scene (2255 East 122nd Street Compton, CA 90222) was not visited by the Coroner personnel.

Evidence:

Physical evidence was collected. On 10/17/2020 at 0241 hours, I utilized a GSR kit on the decedent's face and both his hands at the Decedent Services Unit. Then at 0235 hours, I utilized a fingernail kit to swab underneath all of the decedent's fingernails at the Decedent Services Unit. Then at 0245 hours, I utilized a hair kit to collect hair strands from the decedent's head and face at the Decedent Services Unit. I later booked the GSR kit, the hair kit, and the fingernail kit as evidence at the Forensic Science Center.

Body Examination:

The decedent is a 25-year-old Black male with brown eyes, black hair, natural teeth, an unshaven mustache and a beard. There was a healed linear scar noted to his forehead. There was an irregular shaped scar-like mark noted to his left outer hand. There was a tattoo of the name "Donna" to his upper left chest. There was a tattoo of the letter "Y" on his lower right leg. There was a tattoo of the letter "M" on his lower left leg. There was a tattoo of multiple designs/symbols noted to both of his arms and his chest area. No other scars or tattoos were noted. The decedent was wearing blue pants, blue underwear, white socks, and black shoes. The decedent was seen lying supine on the ground. The top of his head was facing north, with both of his arms resting by his sides. Both of his legs were straight, with both of his feet pointing south. There were multiple EKG pads on his torso. There was a bandage placed over his left inner elbow. There was an apparent gunshot wound seen to his left upper back with a gauze and tape coverage. There were skin anomalies noted to his lower chest, his front neck, and his upper and lower back that could possibly be due to act activity. Rigor mortis was rated to be about a 2 throughout his body. Lividity was light in color, seen to his backside, and blanched with pressure.

Identification:

The DOJ and FBI positively identified the decedent as WILLIAMS, FRED with a DOB of 02/11/1995 by his fingerprints via LiveScan.

Next of Kin Notification:


The decedent's [REDACTED] has been notified of the decedent's death. The decedent does not have a will, is not legally married, and has no children.


Tissue Donation:

Not addressed.

Autopsy Notification:

Detective Dimmitt and Sergeant O'Brien from LASD Homicide are requesting a two-hour notification prior to the examination. Please see case notes for their private contact information.


LIANNA DARABEDYAN #646370


SUPERVISOR

10/18/2020

Date of Report