

**12****AUTOPSY REPORT**No. 2020-09624  
YOUNG, JR, DANA  
MITCHELLI performed an autopsy on the body of at THE DEPARTMENT OF CORONERLos Angeles, California on October 23, 2020 1400  
(Date) (Time)From the anatomic findings and pertinent history I ascribe the death to:(A) Multiple gunshot wounds

DUE TO OR AS A CONSEQUENCE OF

(B)

DUE TO OR AS A CONSEQUENCE OF

(C)

MANNER OF DEATH

Homicide

HOW INJURY OCCURRED:

With handgun*Anatomical Summary:*Summary:

- 4 total gunshot wounds
  - o #1 to the head is fatal
  - o #2 to the back is potentially fatal
  - o #3 and 4 are non-fatal
- Also present:
  - o 1 graze wound on the left anterior thigh
  - o Avulsion of the upper lip and large abrasions of the anterior and left face.
  - o Scattered abrasions on the extremities, abdomen, back
- All bullets travel left to right and up through the body. Gunshot wounds 1 and 2 also travel back to front.
- 3 deformed jacketed bullets are recovered and submitted to evidence.
- Soot, stippling, searing, or muzzle stamp was not seen on any of the gunshot wounds.

Gunshot wound #1, fatal

- Enters the left back of head, 2" below top of head, 1" left of midline, 3/16" round wound with abrasion collar.
- Bullet perforates the:
  - o Left posterior parietal skull, internal bevel
  - o Left posterior parietal lobe and right anterior parietal lobe.
- Bullet ricochets off the right inner anterior parietal skull causing a round elevated fracture, 3" right and 4" anterior to the entrance wound.

- Bullet recovered from the right frontal lobe

Gunshot wound #2, potentially fatal

- Enters the left buttock, 32" below top of head, 3 ½" left of midline, 1/8" round wound with inferior marginal abrasion.
- Bullet perforates the:
  - o Left ilium (pelvis bone)
  - o Left psoas muscle
  - o Mesocolon
  - o Mesentery
- About 300 cc hemoperitoneum
- Bullet recovered from just posterior to the left liver lobe.

Gunshot wound #3, non-fatal

- Enters the right lower abdomen, 31" below top of head, 2" right of midline, 3/8" round wound with 1 ¼" inferior marginal abrasion.
- Bullet perforates the subcutaneous tissue.
- Bullet is palpable and recovered from subcutaneous right upper abdomen, 26" below top of head, 3" right of midline.

Gunshot wound #4, non-fatal

- Superficial through-and-through wound of the penis.
- 1" and ½" irregular wounds on the anterior surface of the penis (in the flaccid position, pointing down towards the feet)
- The trajectory through the flaccid penis is approximately parallel to gunshot wound #3
- Direction is unknown.

Graze wound:

- 1 ¼" wound of the left anterior thigh, 45" below top of head.
- The trajectory is approximately parallel to gunshot wound #3
- Direction is unknown.

Facial wounds:

- ¾ x ¼" full thickness avulsion of the left upper lip.
- The upper and lower inner lips show lacerations and torn frenulae.
- Upper central incisors are chipped
- 4 ½ x ½" abrasion across the left forehead
- 2 x 2" abrasion down the left temple/cheek
- Nasal abrasions and laceration

Scattered small abrasions on the left shoulder and forearm, left abdomen, both knees, right lower back, and right posterior hand.

For purposes of identification and convenience, injuries are arbitrarily numbered and this is not an opinion as to the order in which these wounds were sustained.

Please see separate toxicology report.

**CIRCUMSTANCES:**

Please see Investigator's Report.

**EXTERNAL EXAMINATION:**

The body is identified by toe tags and is that of an unembalmed refrigerated adult black male who appears the reported age of 47 years. The body measures 69 inches, weighs 157 pounds, and is normally developed. Hydration and nutritional status are grossly normal. Examination of the skin reveals no evidence of jaundice. Scars: left shoulder. Tattoos: "West 28th st" right calf, "Baltimore Ravens" left calf, "Helen" left shoulder, and multiple others. Rigor mortis is mild. Livor mortis is fixed and posterior.

The head is normal in size and shape. The scalp hair is short and black in color. Mustache is present. Beard is present. Examination of the eyes reveals irides that appear to be brown in color and sclerae that are white. The conjunctivae are not congested. There are no petechial hemorrhages of the

# 12

## AUTOPSY REPORT

No. 2020-09624  
YOUNG, JR, DANA  
MITCHELL

Page 4

conjunctivae of the lids or the sclerae. The oronasal passages are unobstructed. There is no foam in the nares or oral cavity. Upper and lower teeth are present. Examination of the neck shows no abnormal mobility, fingernail marks, contusions, or abrasions.

There is no chest deformity. There is no increased anterior-posterior diameter. The abdomen is not unusual. The genitalia are those of an adult male.

### **EVIDENCE OF THERAPEUTIC INTERVENTION:**

None seen. Recent needle punctures are absent. There has not been post mortem intervention for organ procurement.

### **INITIAL INCISION:**

The body cavities are entered through the standard coronal incision and the standard Y-shaped incision. No foreign material is present in the mouth, upper airway, and trachea.

### **NECK:**

The neck organs are removed en bloc with the tongue. No lesions are present nor is trauma of the gingiva, lips, or oral mucosa demonstrated. There is no edema of the larynx. Both hyoid bone and larynx are intact and without fractures. No hemorrhage is present in the adjacent throat organs investing fascia, strap muscles, thyroid, or visceral fascia. There are no prevertebral fascial hemorrhages. The tongue when sectioned shows no trauma. No fractures of the cervical vertebrae are present.

### **CHEST/ABDOMINAL CAVITY:**

There are no pleural effusions or adhesions. No blood (0 cc) is present in either pleural cavity. The parietal pleurae are intact. Soft tissues of the thoracic and abdominal walls are well-preserved. The organs of the abdominal cavity have a normal arrangement and none are absent. Ascites is not present. The peritoneal cavity is without evidence of peritonitis. There are no adhesions.

**SYSTEMIC AND ORGAN REVIEW:**

Note: The conditions appearing in the Anatomic Summary and Description of Injuries are not necessarily repeated in the Systemic Review. The systemic review is, in essence, a description of the decedent prior to sustaining injuries. All diagrams and descriptions are made using the standard anatomic position at all times.

**MUSCULOSKELETAL SYSTEM:**

No abnormalities of the uninjured bony framework or muscles are identified.

**CARDIOVASCULAR SYSTEM:**

The thoracic and abdominal aorta have no atherosclerosis. There is no tortuosity or widening of the thoracic segment. There is no dilation of the lower abdominal segment. No aneurysm is present. The major branches of the aorta show no abnormality. Within the pericardial sac there is a minimal amount of serous fluid.

The heart weighs 300 grams. It has a normal configuration. The cardiac silhouette is not globular and the myocardium is not flabby. The right ventricle is 0.3 cm, the interventricular septum is 1.2 cm in thickness, and the left ventricle is 1.3 cm in thickness. The chambers are normally developed and are without mural thrombosis. The valves are thin, leafy, and competent. No cardiac valve vegetations are present. Circumferences of the valve rings are within normal limits. There is no endocardial discoloration. There are no infarcts or lesions of the myocardium. There is no abnormality of the apices of the papillary musculature. There are no defects of the septum. The great vessels enter and leave in a normal fashion. The ductus arteriosus cannot be probed. The coronary ostia are patent, located at or below the sinotubular junction and are relatively centrally located within their respective sinuses. The coronary artery distribution is right dominant. Serial sectioning of the coronary arteries show mild atherosclerosis of the LAD; the other coronaries are clean.

# 12

## AUTOPSY REPORT

No. 2020-09624  
YOUNG, JR, DANA  
MITCHELL

Page 6

### **RESPIRATORY SYSTEM:**

Scant secretions are found in the upper respiratory and lower bronchial passages. No froth or soot is present in the upper or lower airway. The mucosa is intact and pale. The lungs are subcrepitant and there is dependent congestion. The right lung weighs 550 grams and the left lung weighs 550 grams. The visceral pleurae are smooth and intact. The pulmonary vasculature is without thromboembolism. There is no evidence of pulmonary infarction.

### **GASTROINTESTINAL SYSTEM:**

The esophagus is intact throughout. Esophageal varices are not present. The stomach is empty and the mucosa is unremarkable. The small intestine and colon are unremarkable. The appendix is present and normal. The pancreas occupies a normal position. There is no necrosis or trauma. There is no evidence of pancreatic fibrosis or of pancreatitis.

### **HEPATOBIILIARY SYSTEM:**

The liver weighs 820 grams, is of average size, and is red-brown in color. The capsule is intact and the consistency of the parenchyma is firm. The cut surface is smooth. There is no evidence of cirrhosis. There is a normal lobular arrangement. The gallbladder is present. The wall is thin and pliable. It contains a moderate amount of bile and no calculi.

### **URINARY SYSTEM:**

The right kidney weighs 100 grams and the left kidney weighs 100 grams. The kidneys are normally situated and the capsules strip easily revealing a surface that is smooth and glistening. The corticomedullary demarcation is preserved. The pyramids are not remarkable. The peripelvic fat is not increased. The ureters are without dilation or obstruction and pursue their normal course. The urinary bladder is unremarkable. It contains approximately 100 cc of clear, yellow urine.

**GENITAL SYSTEM:**

The prostate is without enlargement or nodularity. Both testes are in the scrotum and are unremarkable and without trauma.

**HEMOLYMPHATIC SYSTEM:**

The spleen weighs 90 grams and is of average size. The capsule is intact. The parenchyma is dark red and soft. There is no increased follicular pattern. Lymph nodes throughout the body are small and inconspicuous. The bone is not remarkable. The bone marrow of the rib is unremarkable.

**ENDOCRINE SYSTEM:**

The thyroid, adrenal, and pituitary glands are unremarkable. The parathyroid glands are not identified. The thymus is the usual appearance for the age.

**SPECIAL SENSES:**

The eyes are not dissected. The middle and inner ear are not dissected.

**HEAD AND CENTRAL NERVOUS SYSTEM, excluding trauma:**

The brain weighs 1520 grams. The leptomeninges are thin and transparent. A normal convolutionary pattern is observed. Coronal sectioning demonstrates a uniformity of cortical gray thickness. The cerebral hemispheres are symmetrical. There is no natural pathology of the white matter seen. Pons, medulla, and cerebellum are unremarkable. There is no evidence of uncal or cerebellar herniation. Vessels at the base of the brain have a normal pattern of distribution. There are no aneurysms. The cerebral arteries are without arteriosclerosis.

**SPINAL CORD:**

The cord is not dissected.

**EVIDENCE COLLECTION:**

Three bullets are recovered from the decedent, each placed separately in small labeled envelopes and sealed. The small envelopes are all placed in 1 large labeled envelope, sealed

# 12

## AUTOPSY REPORT

No. 2020-09624  
YOUNG, JR, DANA  
MITCHELL

Page 8

with evidence tape, signed and dated across the seal, and placed in evidence drop box.

### HISTOLOGIC SECTIONS:

Representative sections from various organs are preserved in one storage jar.

### TOXICOLOGY:

Samples of heart and femoral blood, urine, and vitreous are submitted to the laboratory for homicide screen. An EDTA tube is collected for DNA.

### PHOTOGRAPHY:

At scene photos are available. Photographs have been taken prior to the course of the autopsy.

### RADIOLOGY:

4 x-rays are taken and show the bullets described above.

### WITNESSES:

Detective Jason Marx, LASD.  
Investigator Charles Garcia, District Attorney's office  
Inspector Daysi Alarcon, Office of Inspector General

### DIAGRAMS USED:


Diagram forms #20, 28, 43, 22, 20, 20 were used during the performance of the autopsy. Coroner diagrams are not intended to be facsimiles nor are they drawn to scale.

### OPINION:

The cause of death is multiple gunshot wounds. The range of fire is unknown by autopsy. The manner of death is homicide.



Kevin Young, M.D.  
Deputy Medical Examiner



Date



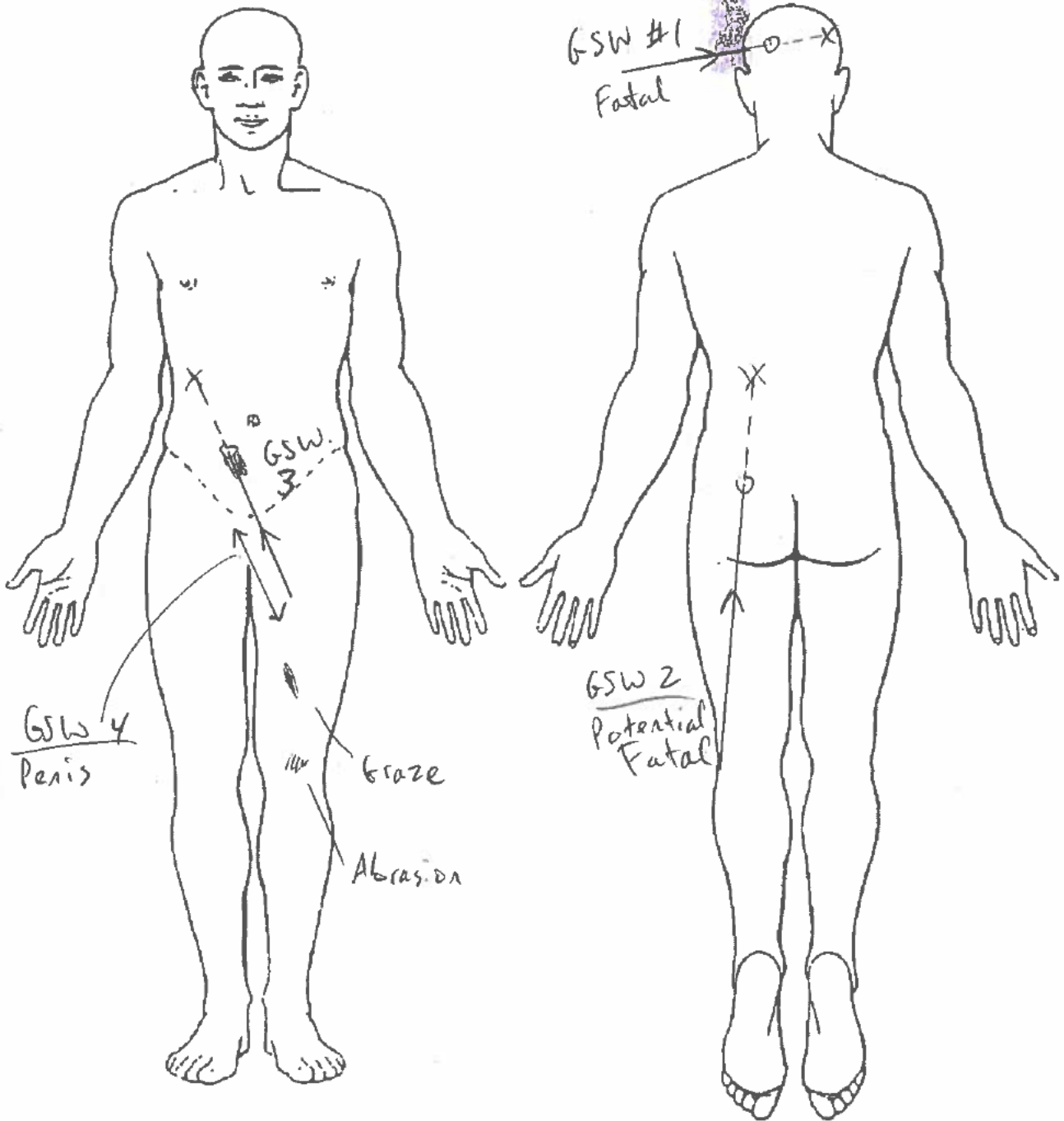
20

1/6

GSWs 1-4  
X = Bullet

2020-09624

YOUNG, JR, DANA MITCHELL



Date OCT 23 2020

104

Kevin Young, MD

M.D.

Deputy Medical Examiner

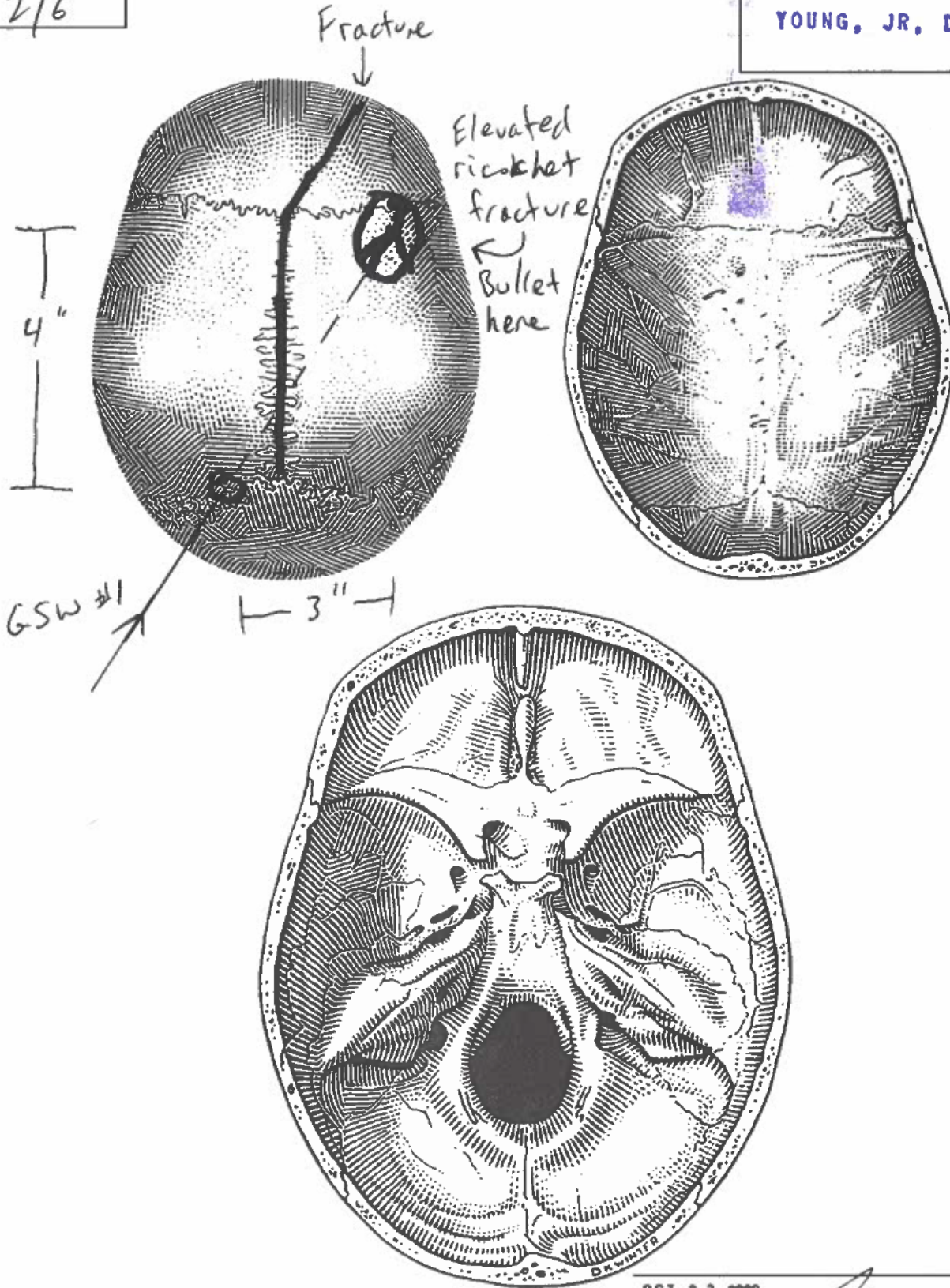
28

2/6

GSW #1

2020-09624

YOUNG, JR, DANA MITCHELL



GSW #1

3"

OCT 23 2020

Kevin Young, MD

M.D.

Deputy Medical Examiner

MISCELLANEOUS WORK SHEET

43


3/6

Right

Left

1/2" wound

1" wound



2020-09624

YOUNG, JR, DANA MITCHELL

GSW #4

Penis

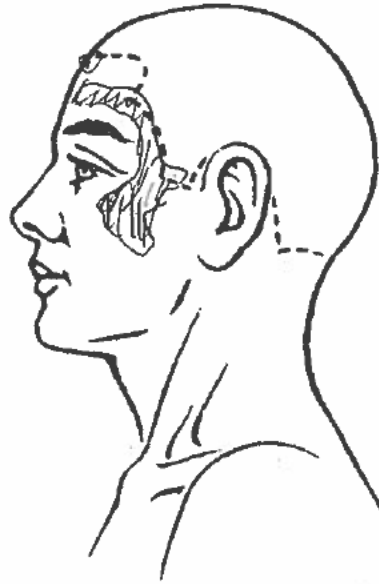
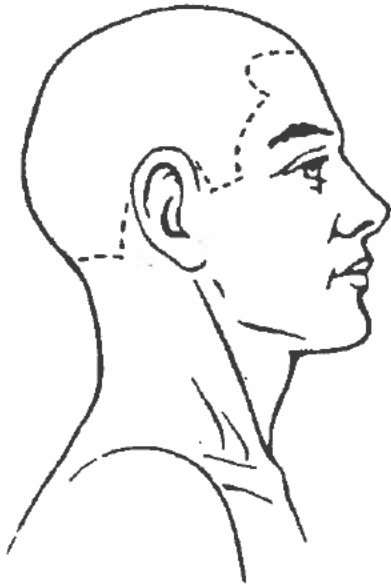
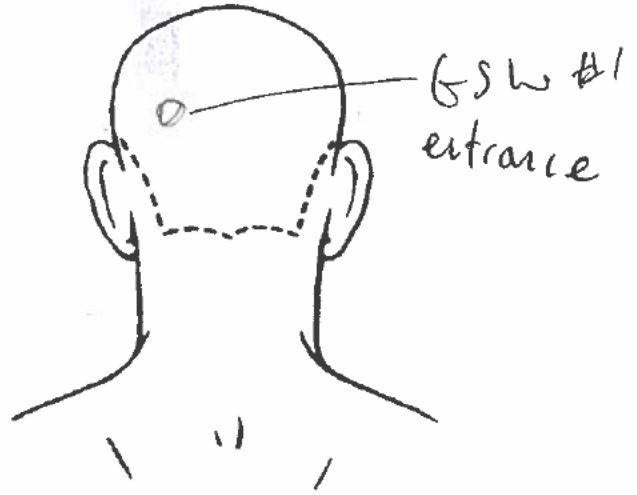
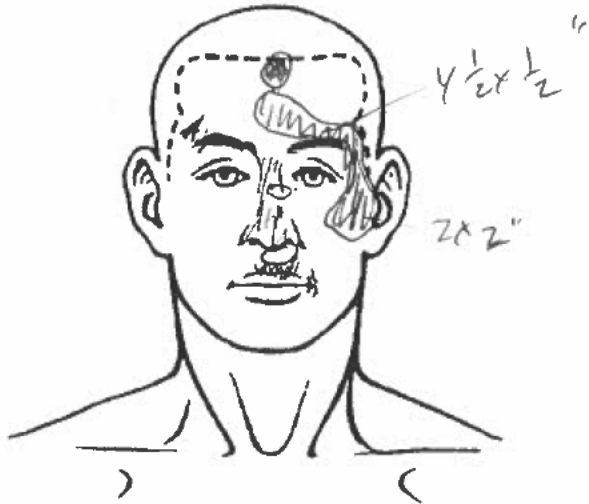
Date 10/23/20 *JS*  
 Kevin Young  
 Deputy Medical Examiner

M.D.

22  
4/6

MM = Abrasion  
O = Avulsion / Laceration

2020-09624  
YOUNG, JR, DANA MITCHELL



Date OCT 23 2020

Kevin Young, MD

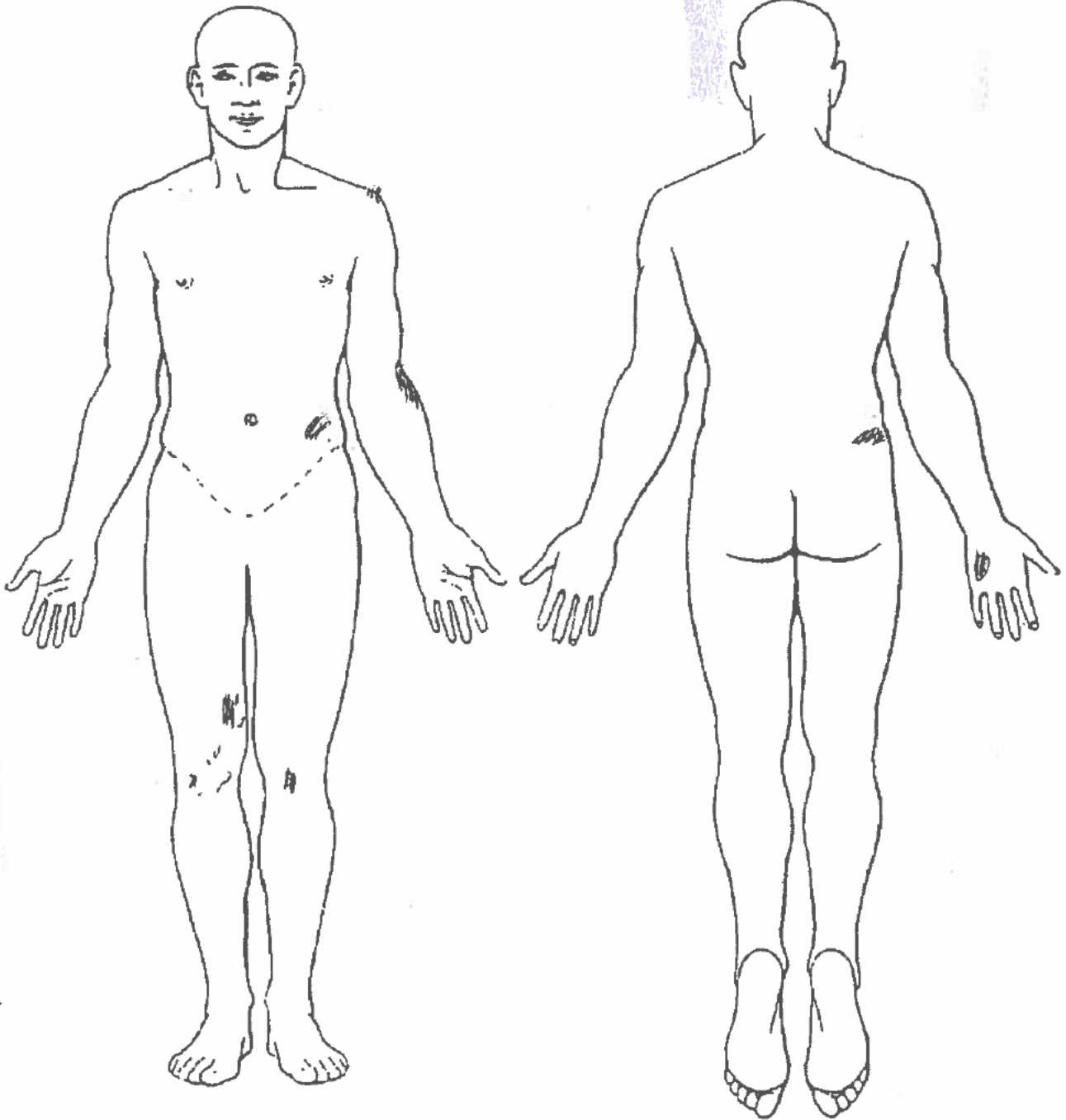
M.D.

Deputy Medical Examiner

20  
5/6

Abrasions

2020-09624  
YOUNG, JR, DANA MITCHELL



Date OCT 23 2020

Kevin Young, MD

M.D.

Deputy Medical Examiner

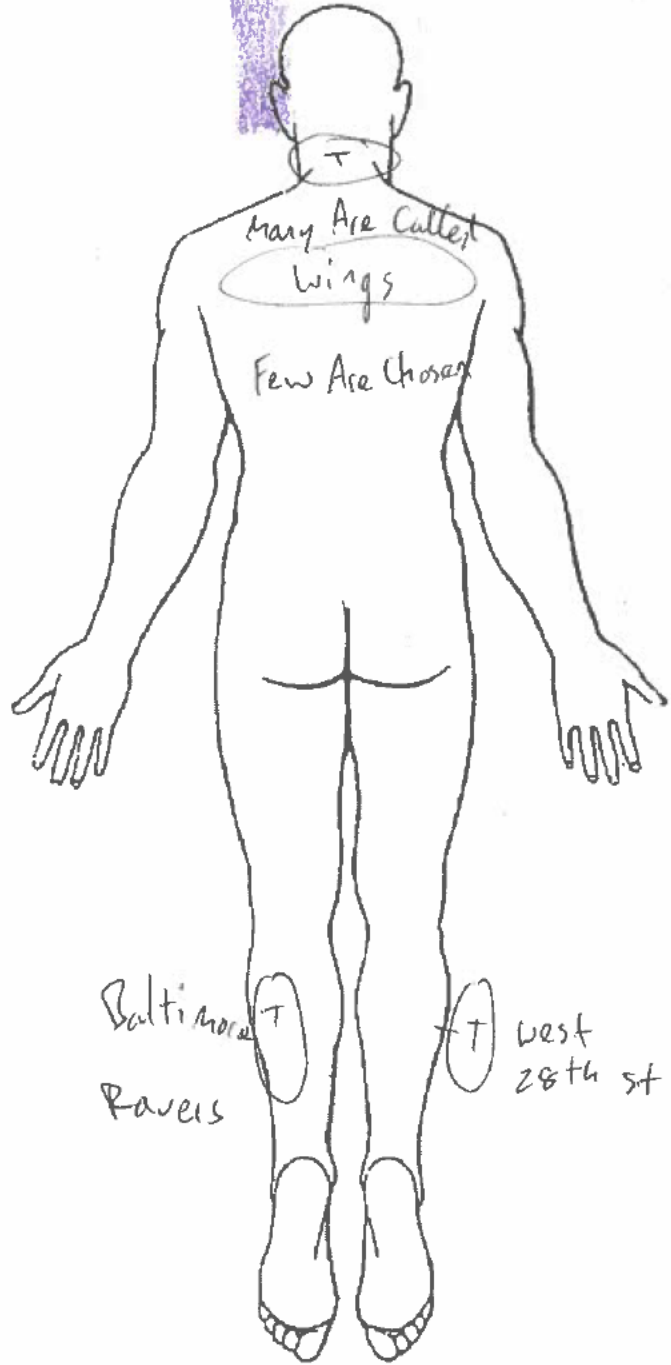
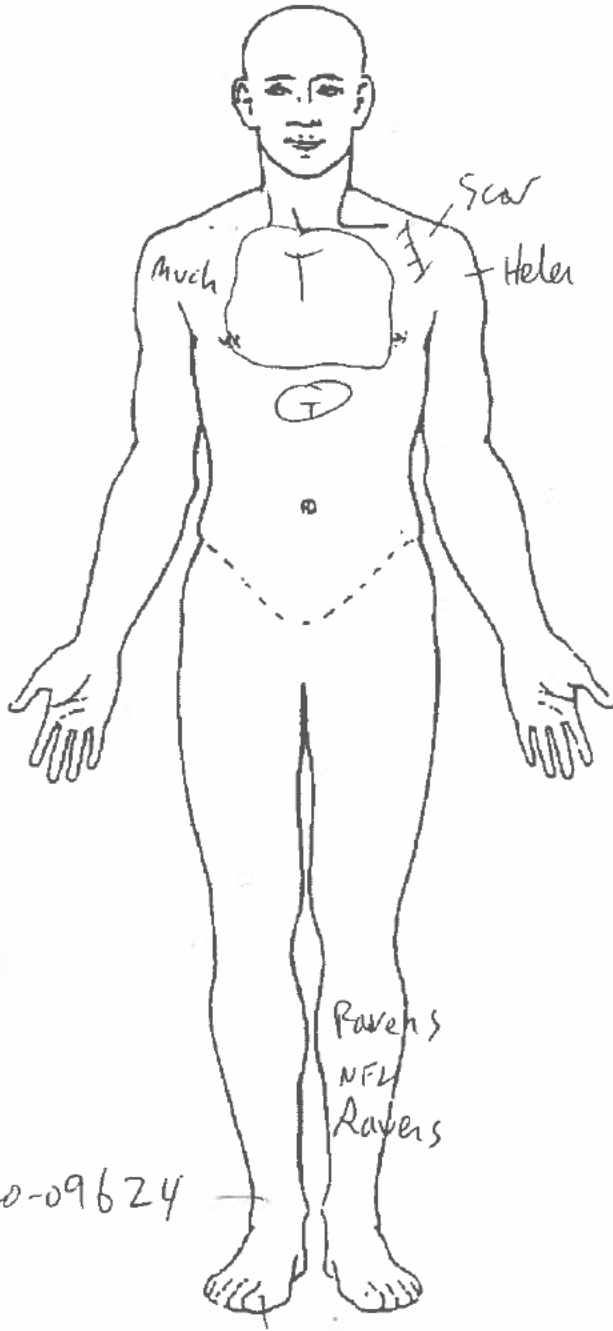
20  
6/6

(T) = Tattoos

2020-09624

YOUNG, JR, DANA MITCHELL

Sleeve tattoos



20-09624

2020-09624  
Young, Dana Mitchell Jr.

Date OCT 23 2020

Kevin Young, MD

Deputy Medical Examiner

M.D.



15

AUTOPSY CLASS:  A  B  C  Examination Only D

FAMILY OBJECTION TO AUTOPSY

Date: 10/23/20 Time: 1400 Dr. Young

FINAL ON: 10/23/20 By: Young

APPROXIMATE INTERVAL BETWEEN ONSET AND DEATH

2020-09624  
YOUNG, JR., DANA MITCHELL

DEATH WAS CAUSED BY: (Enter only one cause per line for A, B, C, and D)

IMMEDIATE CAUSE:

(A) Multiple gunshot wounds

DUE TO, OR AS A CONSEQUENCE OF:

(B)

DUE TO, OR AS A CONSEQUENCE OF:

(C)

DUE TO, OR AS A CONSEQUENCE OF:

(D)

OTHER CONDITIONS CONTRIBUTING BUT NOT RELATED TO THE IMMEDIATE CAUSE OF DEATH:

NATURAL  SUICIDE  HOMICIDE  
 ACCIDENT  COULD NOT BE DETERMINED

If other than natural causes, HOW DID INJURY OCCUR?

with handgun

WAS OPERATION PERFORMED FOR ANY CONDITION STATED ABOVE:  YES  NO

TYPE OF SURGERY: \_\_\_\_\_ DATE: \_\_\_\_\_

ORGAN PROCUREMENT  TECHNICIAN: Sergio  
PREGNANCY IN LAST YEAR  YES  NO  UNK  NOT APPLICABLE

WITNESS TO AUTOPSY  EVIDENCE RECOVERED AT AUTOPSY

3  
Item Description: 3 bullets  
Deposit 10/23/20  
ky

Age: 47 Gender: Male / Female

PRIOR EXAMINATION REVIEW BY DME

BODY TAG  CLOTHING  
 X-RAY (No. 4)  FLUORO  
 SPECIAL PROCESSING TAG  MED. RECORDS  
 AT SCENE PHOTOS (No. 71)

CASE CIRCUMSTANCES

EMBALMED  
 DECOMPOSED  
 >24 HRS IN HOSPITAL  
 OTHER: \_\_\_\_\_ (Reason)

TYPING SPECIMEN

TYPING SPECIMEN TAKEN BY: ky  
SOURCE: H

TOXICOLOGY SPECIMEN

COLLECTED BY: ky  
 HEART BLOOD  STOMACH CONTENTS  
 FEMORAL BLOOD  VITREOUS  
TECHNIQUE:  
 \_\_\_\_\_ BLOOD  SPLEEN  
 \_\_\_\_\_ BLOOD  KIDNEY  
 BILE  \_\_\_\_\_  
 LIVER  \_\_\_\_\_  
 URINE  \_\_\_\_\_

URINE GLUCOSE DIPSTICK RESULT: 4+ 3+ 2+ 1+ 0  
TOX SPECIMEN RECONCILIATION BY: \_\_\_\_\_

HISTOLOGY

Regular (No. 1)  Oversize (No. \_\_\_\_\_)  
Histopath Cut:  Autopsy  Lab

TOXICOLOGY REQUESTS

FORM 3A:  YES  NO  
 NO TOXICOLOGY REQUESTED  
SCREEN  C  H  T  S  D  
 ALCOHOL ONLY  
 CARBON MONOXIDE  
 OTHER (Specify drug and tissue)

REQUESTED MATERIAL ON PENDING CASES

POLICE REPORT  MED HISTORY  
 TOX FOR COD  HISTOLOGY  
 TOX FOR R/O  INVESTIGATIONS  
 MICROBIOLOGY  EYE PATH. CONS.  
 RADIOLOGY CONS.  
 CONSULT ON: \_\_\_\_\_  
 BRAIN SUBMITTED  
 NEURO CONSULT  DME TO CUT  
 CRIMINALISTICS  
 GSR  SEXUAL ASSAULT  OTHER

RESIDENT

DME



Department of Medical Examiner-Coroner, County of Los Angeles

# FORENSIC SCIENCE LABORATORIES

1104 North Mission Road, Los Angeles, CA 90033

## Laboratory Analysis Summary Report



Young, Kevin M.D.

Deputy Medical Examiner  
1104 North Mission Road  
Los Angeles, CA 90033

PendingTox

**Coroner Case Number:** 2020-09624    **Decedent:** YOUNG JR., DANA MITCHELL

<u>SPECIMEN</u>	<u>SERVICE</u>	<u>DRUG</u>	<u>RESULT</u>	<u>ANALYST</u>
-----------------	----------------	-------------	---------------	----------------

### Alcohol Quantitation/Confirmation

Blood, Heart

Alcohol-GC/FID-HS	Ethanol	Negative	C. Castellino
-------------------	---------	----------	---------------

### Drug Screen

Blood, Heart

ELISA-Immunoassay	Benzodiazepines	ND	J. Posada
ELISA-Immunoassay	Cocaine and Metabolites	ND	J. Posada
ELISA-Immunoassay	Fentanyl	ND	J. Posada
ELISA-Immunoassay	Marijuana: 11-nor-Delta-9-Carboxy-THC	PP	J. Posada
ELISA-Immunoassay	Methamphetamine & MDMA	ND	J. Posada
ELISA-Immunoassay	Opiates: Codeine & Morphine	ND	J. Posada
ELISA-Immunoassay	Opiates: Hydrocodone & Hydromorphone	ND	J. Posada
ELISA-Immunoassay	Phencyclidine	ND	J. Posada

### Drug Screen/Confirmation

Blood, Heart

Bases-GC/NPD &/or MS	Basic Drugs	ND	B. Helmer
Cannabinoids-LC/MS/MS	11-nor-Delta-9-Carboxy-THC, Free	ND	M. Liebl
Cannabinoids-LC/MS/MS	Delta 9-Tetrahydrocannabinol (THC), Free	ND	M. Liebl

*Ku 12/24/20*



Coroner Case Number: 2020-09624 Decedent: YOUNG JR., DANA MITCHELL

SPECIMEN   SERVICE                      DRUG    RESULT              ANALYST

**Legend:**

g	Grams	ND	Not Detected	SNS	Specimen Not Suitable
g%	Gram Percent	ng/g	Nanograms per Gram	TNP	Test Not Performed
Inc	Inconclusive	ng/mL	Nanograms per Milliliter	ug	Micrograms
mg	Milligrams	PP	Presumptive Positive	ug/g	Micrograms per Gram
		QNS	Quantity Not Sufficient	ug/mL	Micrograms per Milliliter

The alcohol analysis was performed in accordance to California Code of Regulations "Title 17" compliance by a qualified analyst in the Forensic Toxicology Laboratory, Forensic Laboratories Division, County of Los Angeles Department of Medical Examiner - Coroner.

Enzyme-linked immunosorbent assay (ELISA) provides only a preliminary analytical result that is contingent upon a confirmatory test. A "presumptive positive" (PP) signifies a detection of a drug class and must be confirmed by additional testing for true identification and/or quantitation of specific drug(s) present in the specimen.

Per the Department's Evidence Retention Policy, the blood specimen(s) will be retained for one year (minimum) and all other specimens six months (minimum) from Postmortem Exam.

Final Review By:



Sarah Buxton de Quintana  
Supervising Criminalist I

Date:

11/17/20

*The above results relate only to the items sampled and tested and have been technically and administratively reviewed and are the opinions and conclusions of the analysts noted. The final review has been certified by the noted Toxicologist to ensure that all standard operating procedures were followed as set by the Forensic Toxicology Laboratory, Forensic Sciences Laboratory Division, County of Los Angeles Department of Medical Examiner-Coroner.*

A Young

COUNTY OF LOS ANGELES

CASE REPORT

DEPARTMENT OF CORONER


1	APPARENT MODE <b>HOMICIDE</b>	CASE NO 2020-09624
	SPECIAL CIRCUMSTANCES Gunshot Wound, Officer Involved	CRYPT 19

LAST, FIRST MIDDLE <b>YOUNG, JR, DANA MITCHELL</b>	AKA <b>YOUNG, DANA MITC</b>	#
---	--------------------------------	---

ADDRESS	CITY	STATE	ZIP
---------	------	-------	-----

SEX MALE	RACE APPEARS BLACK	DOB 1/30/1973	AGE 47	HGT 69 in.	WGT 157 lbs.	EYES BROWN	HAIR BLACK	TEETH INCOMPLETE	FACIAL HAIR BEARD AND MUSTACHE	ID VIEW Yes	CONDITION HEAD TRAUMA
-------------	-----------------------	------------------	-----------	---------------	-----------------	---------------	---------------	---------------------	-----------------------------------	----------------	--------------------------

MARK TYPE	MARK LOCATION	MARK DESCRIPTION
SCAR	LEFT SHOULDER	CIRCULAR
TATTOO	BACK	WORDS, WINGED FIGURE
TATTOO	BOTH LEGS	LOGOS, FIGURE, CAT



ID METHOD  
FINGERPRINTS



IDENTIFIED BY NAME (PRINT)	RELATIONSHIP	PHONE	DATE	TIME
CALPHOTO, LACRIS, DOJ, FBI			10/15/2020	20:08

PLACE OF DEATH / PLACE FOUND SIDEWALK	ADDRESS OR LOCATION W. 108TH STREET, WEST OF S. VERMONT AVENU	CITY LOS ANGELES	ZIP 90044
--	--	---------------------	--------------

PLACE OF INJURY STREET	AT WORK No	DATE 10/15/2020	TIME	LOCATION OR ADDRESS W. 108TH STREET, WEST OF S. VERMONT AVENUE, LOS ANGELES, CA	ZIP 90044
---------------------------	---------------	--------------------	------	--	--------------

DOD 10/15/2020	TIME 04:12	FOUND OR PRONOUNCED BY LACF ENG 14 BALDERAMA
-------------------	---------------	---

OTHER AGENCY INV. OFFICER LASD HOMICIDE - SGT. SHROUT	PHONE (323) 890-5500	REPORT NO 020087750375013	NOTIFIED BY	NO
--	-------------------------	------------------------------	-------------	----

TRANSPORTED BY JAMES ESTEL	TO LOS ANGELES FSC	DATE 10/15/2020	TIME 19:38
-------------------------------	-----------------------	--------------------	---------------

FINGERPRINTS? Yes	CLOTHING Yes	PARPT No	MORTUARY
MED. EV. Yes	INVEST. PHOTO # 71	SEAL TYPE NOT SEALED	HOSP RPT No
PHYS. EV. Yes	EVIDENCE LOG Yes	PROPERTY? Yes	HOSP CHART No
SUICIDE NOTE No	GSR NO	RCPT NO. 322559	PF NO.

SYNOPSIS  
 ACCORDING TO THE PRELIMINARY LASD HOMICIDE BUREAU INVESTIGATION, DEPUTIES RESPONDED TO A CALL OF SHOTS FIRED WITH AN ALLEGED KIDNAPPING, AND TRACKED THE VICTIM TO A PARKING LOT; A VEHICLE PURSUIT OCCURRED WHICH CULMINATED IN THE DECEDENT COLLIDING WITH A CIVILIAN VEHICLE. THE DECEDENT EXITED THE VEHICLE, AND A DEPUTY INVOLVED SHOOTING OCCURRED. THERE WERE 5 POSSIBLE GUNSHOT WOUNDS TO THE DECEDENT. THE DECEDENT HAS A HISTORY OF DRUG ABUSE.

JENNIFER HERTZOG 616886	INVESTIGATOR	DATE 10/15/2020 TIME 23:28	REVIEWED BY KELSIE WEBER	DATE 10/16/2020 TIME 01:03
----------------------------	--------------	-------------------------------------	-----------------------------	-------------------------------------

FORM #3 NARRATIVE TO FOLLOW?

10/18/20



## County of Los Angeles, Department of Coroner Investigator's Narrative



Case Number: 2020-09624

Decedent: YOUNG, DANA MITCHELL

### Information Sources:

1. Sergeant Shroul #484677, Sergeant Marx #488425, and Sergeant Jaramilla #456336. Los Angeles Sheriff's Department Homicide Bureau, 1 Cupania Circle, Monterey Park, CA, 91755. 323-890-5500
2. On Scene Investigation.

### Investigation:

On Thursday, 10/15/2020 at 0620 hours, Dispatch Officer Mollinedo #615572 from Los Angeles Sheriff's Department Homicide Bureau reported this apparent homicide death to Gregory Rios, reporting desk, at the Los Angeles County Department of Medical Examiner-Coroner. It was reported that the decedent allegedly kidnapped a victim, was followed by friends, 911 was called, PD pursued, the decedent exited the vehicle, and an officer involved shooting occurred. The decedent was pronounced on scene.

I was assigned this field call by Captain Emily Tauscher on Thursday, October 15, 2020 at approximately 1630 hours.

### Location:

Place of Injury: Street, W. 108<sup>th</sup> Street, west of S. Vermont Avenue, Los Angeles, CA, 90044.

Place of Death: Sidewalk, W. 108<sup>th</sup> Street, west of S. Vermont Avenue, Los Angeles, CA, 90044

### Informant/Witness Statements:

According to Sergeant Shroul at the scene, all information provided was preliminary; the LASD Homicide investigation will be ongoing.

On 10/15/2020, a 911 call was placed for shots fired and an alleged kidnapping. There is video surveillance that shows the alleged kidnapping. Officers confronted the decedent in a borrowed vehicle parked in a parking lot. The decedent fled the scene, and officers pursued in two vehicles. The decedent crashed his vehicle into another vehicle, and the fence. The decedent left his vehicle, and fled on foot. An officer involved shooting occurred with one shooter and one witness. The decedent collapsed face down, and was handcuffed. Los Angeles County Fire Department Engine #14 responded, and Balderama #512017 pronounced at 0412 hours. 8 casings were recovered on scene. 3 rounds were recovered from the fence to the basketball field. The registered owner of the vehicle is possibly the decedent's next-door neighbor. A revolver was recovered from the floorboard of the vehicle with one spent casing.

During my scene investigation, no alcohol, or drug paraphernalia were found. A white tablet was found on the sidewalk near the contents of the decedent's pockets.

Per the Department of Justice, the decedent had multiple prior narcotic related law enforcement encounters from 1992 to 2013.

### Scene Description:

I left the Forensic Science Center at 1650 hours, and I arrived at the scene at 1732 hours. The scene was located on the south side of W. 108<sup>th</sup> Street, west of S. Vermont Avenue. This section of W. 108<sup>th</sup> Street is in a residential area, and ends in a cul-de-sac near an elementary school. There are sidewalks and parked cars on both curbs of the street. There is a metal fence between the south sidewalk and paved fields of the school. On the south sidewalk east of the cul-de-sac, the decedent was located lying prone with his head to the east, and his feet to the west. There were white sandals north of the decedent's feet. The decedent's wallet was south of the decedent's right hip, and a cellphone was north of him. There was a pool of blood running

DM



## County of Los Angeles, Department of Coroner Investigator's Narrative



Case Number: 2020-09624

Decedent: YOUNG, DANA MITCHELL

northeast from the decedent's head, and a pool of blood north of his left hip. I left the scene at 1856 hours, and arrived back at the Forensic Science Center at 1926 hours.

The handgun involved in the shooting was a 9mm pistol model M&P, manufactured by Smith and Wesson. The casings recovered were 9mm Federal Luger rounds.

### **Evidence:**

I collected medical and physical evidence at the scene and at the Forensic Science Center. On 10/15/2020 at 1756 hours, a GSR Kit was collected for the face and hands combined. On 10/15/2020 at 1802 hours, a Fingernail Kit was collected using swabs because the nails were too short for clippings. On 10/15/2020 at 1948 hours, a Hair Kit was collected. An Evidence log was completed, and submitted with the evidence.

### **Body Examination:**

On 10/15/2020 at 1938 hours, the decedent was transported from W. 108<sup>th</sup> Street, west of S. Vermont Avenue, Los Angeles, CA, 90044, and was brought to the Forensic Science Center. The decedent was then processed in the facility at 2005 hours on 10/15/2020 by Forensic Attendant James Estel. At the time of processing, the decedent was recorded with a height of 69 inches and a weight of 157 pounds.

The decedent is an adult Black male who appears to be the reported 47 years of age with short black hair, brown eyes, beard and mustache, and incomplete natural teeth.

The decedent was clothed lying prone on the sidewalk with two pairs of handcuffs connecting his wrists behind his back.

The decedent was wearing a gray hoodie, white undershirt, blue shorts, black shorts, gray underwear, and white socks. A pair of white sandals was near the decedent's feet.

Skin slip was present.

His tongue was clenched between his teeth.

There was a groove around the left wrist. There was a defect to the posterior left hand, and multiple defects to the posterior right hand. There were abrasions to the back and left face.

The decedent had multiple possible gunshot wounds: left buttocks (with corresponding holes in clothing), posterior left head, groin, anterior left upper leg (probable graze with burnt edges), and lower right abdomen (possible graze).

The decedent had multiple tattoos: lateral left lower leg ("Baltimore Ravens" with logo), medial left lower leg (figure with hat, NFL logo, "Ravens"), lateral right lower leg (WB logo, "West 28", cat cartoon), posterior neck ("RIP Denise"), lateral left neck ("Tajanique 8-3-90"), back (winged figure "Many are called, Few are chosen"), full sleeve left arm, full sleeve right arm (1-20-09, face, "Helen", "Elizabeth", "Eric", "Khadijah"), abdomen (lips, symbols), and chest (designs and symbols).

The ambient temperature was 75.0 degrees at 1843 hours. The decedent felt cool to the touch. Lividity was not discernible. Rigor mortis was a 3 throughout.

### **Identification:**

On 10/15/2020 at 2008 hours, the decedent was positively identified by LACRIS fingerprint comparison. On 10/15/2020 at 2020 hours, the decedent was positively identified as Young, Dana Mitchel (DOB 01/30/1973) by Department of Justice and FBI fingerprint comparisons. I confirmed this with California Department of Motor Vehicles Identification [REDACTED] Young, Dana Mitchell Jr.

JAM



County of Los Angeles, Department of Coroner  
Investigator's Narrative



Case Number: 2020-09624

Decedent: YOUNG, DANA MITCHELL

---

**Next of Kin Notification:**

On 10/16/2020 at 1400 hours, Sergeant ShROUT notified the decedent's [REDACTED] of the death via telephone.

**Tissue Donation:**

Tissue donation was not discussed with family due to the delay in notification.

**Autopsy Notification:**

Sergeant ShROUT and Sergeant Marx from Los Angeles Sheriff's Department Homicide Bureau request a TWO-HOUR exam notice. Please see case notes for contact information.

  
\_\_\_\_\_  
JENNIFER HERTZOG

  
\_\_\_\_\_  
ACTING SUPERVISOR

10/17/2020  
\_\_\_\_\_

Date of Report